

Treatment of wrist and hand fractures with natural magnets: preliminary report

Cosimo Costantino¹, Francesco Pogliacomì¹, Francesco Passera², Galeazzo Concari³

¹Orthopaedics, Traumatology and Functional Rehabilitation Unit, Department of Surgical Sciences; ²Orthopaedic Nurse, Parma Hospital; ³Orthopaedic Division, Parma Hospital

Abstract. The Authors, after having defined the phenomenon and the biological characteristics of natural magnets, evaluate their ability in accelerating the formation of bone callus in hand and wrist fractures compared to treatment with immobilization in a plaster cast. Forty patients (4 females and 37 males) between 20 and 86 years of age were treated. A small natural magnet was inserted in each of the plaster casts (diameter: 2cm, height: 0.5cm) made of 4 blocks in Neodymium-Iron-Boron, capable of generating 4 magnetic poles (2 positive and 2 negative) of diagonal alternate polarity that produced a symmetric, quadruple static magnetic field. The created magnetic flow was wavelike, concentrated in one direction, and developed a force up to 12,500 gauss. From this study it has emerged that inserting a quadruple magnet in a plaster cast in hand and wrist fractures results in the formation of bone callus in an average time that is 35% inferior to the “standard” time. Accelerating the healing of the fracture is important since it reduces immobilization time for the joints involved, avoiding subsequent weakness and stiffness and allowing the patient to begin rehabilitative physiotherapy sooner, which permits a faster functional recovery. (www.actabiomedica.it)

Key words: Fractures, hand, wrist, natural magnet

Introduction

Magnetism is a phenomenon that spontaneously exists in nature, especially in bodies called iron magnets that, with the intervention of electric fields, create forces of attraction or repulsion localized in their ends (magnetic poles).

In order to have an even magnetic field in a certain area it is sufficient to make a current flow in a wire or a solenoid.

If the electric current that is generated has a pulsate flow, a pulsed electromagnetic field (PEMF) is created whereas if the current is continuous and constant, the magnetic field will be static (1).

Magnetic therapy is presently widely used in clinical practice due to its anti-inflammatory and positive effects on tissues. It is based on the application of

static or pulsed magnetic fields with the aim of activating the natural electromagnetic impulses of the human body.

The biological effects, therefore determined, are related to the characteristics of the field (direction, intensity, frequency, and type of wave) and to the receiving state of each individual.

The magnetic fields used in medicine are of low frequency (0-100 Hz) and low intensity (5-100 Gauss) and their effects are carried out on different levels leading to:

- an increase of permeability of plasmatic membranes;
- an increase of enzyme and cytochrome activity;
- an improvement of blood circulation;
- an increase of immunity defenses;
- effects on metabolism;

- effects on cellular reproduction;
- effects on the regeneration of tissues (activation of fibroblasts with the production of collagen and angiopoiesis with vascular neoformation);
- effects on bone tissue [stimulation of osteogenesis by activation of osteoblasts, increase of blood supply and inhibition of parathyroid hormone (PTH)] (2-11).

In nature, beside the inducted magnetic fields, there are also the "Stable spontaneous magnetic fields" produced by natural magnets existing in nature. The most common and widely used are the "Rare earth magnets" (Samarium-Cobalt and Neodymium-Iron-Boron).

Neodymium in particular, is able to develop a force that is 10 times higher than the force produced by traditional magnetic materials.

Magnets, of various dimensions and force, built with these materials, are being used in the medical field for "stable field magnetic therapy", by placing the magnet in direct contact with the specific body areas to be treated.

These materials can have different shape (bracelet, necklace, belt, plate etc.) and have a polarity that can be distributed in variable ways (monopolar, bipolar, quadrupolar etc.).

The efficiency of the treatment with natural magnets depends on several parameters: force expressed in Gauss, type of pole used, dimension of the magnet, body surface in contact with the magnet, and time of exposure.

Their effect consists in the penetration of the magnetic flow of 2-5cm through the skin and in the stimulation of the material encountered (mostly the iron found in haemoglobin and oxygen) along with anti-inflammatory effects and tissue healing without side effects.

The purpose of this study was to evaluate the ability of natural magnets in accelerating the formation of bone callus in hand and wrist fractures.

Materials and methods

At the orthopaedic emergency room of Parma Hospital, from 2004 to 2006, 40 patients (4 females and 37 males) between 20 and 86 years of age, with

wrist and hand fractures, were treated with the association of immobilization in cast and natural magnets.

Magnets of small dimensions, (diameter: 2cm and height: 0.5cm) made of 4 blocks of Neodymium-Iron-Boron, capable of generating 4 magnetic poles (2 positive and 2 negative) at alternate diagonal polarity, thus creating a symmetrical quadrupolar and static magnetic field, were used (Fig. 1).

The magnetic flow created was wavelike, concentrated in a single direction and developed a force up to 12,000 Gauss (Fig. 2).

The type of fractures were the following:

- 8 fractures of distal radial epiphysis of which: 4 fractures with dorsal bone dislocation without metaphyseal fragmentation (Fig. 3), 3 fractures with dorsal bone displacement with metaphyseal fragmentation, and 1 fracture without bone dislocation.
- 18 fractures of the carpal scaphoid without bone dislocation.
- 10 fractures of the metacarpal bone of which 8 with and 2 without bone dislocation (Fig. 4).
- 4 fractures of the proximal phalanx of the fingers with bone dislocation.



Figure 1. "Rare earth" quadrupolar magnets in which 4 blocks are highlighted




Figure 2. Representation of the wavelike magnetic field with 2 positive and 2 negative magnetic poles that alternate diagonally and symmetrically

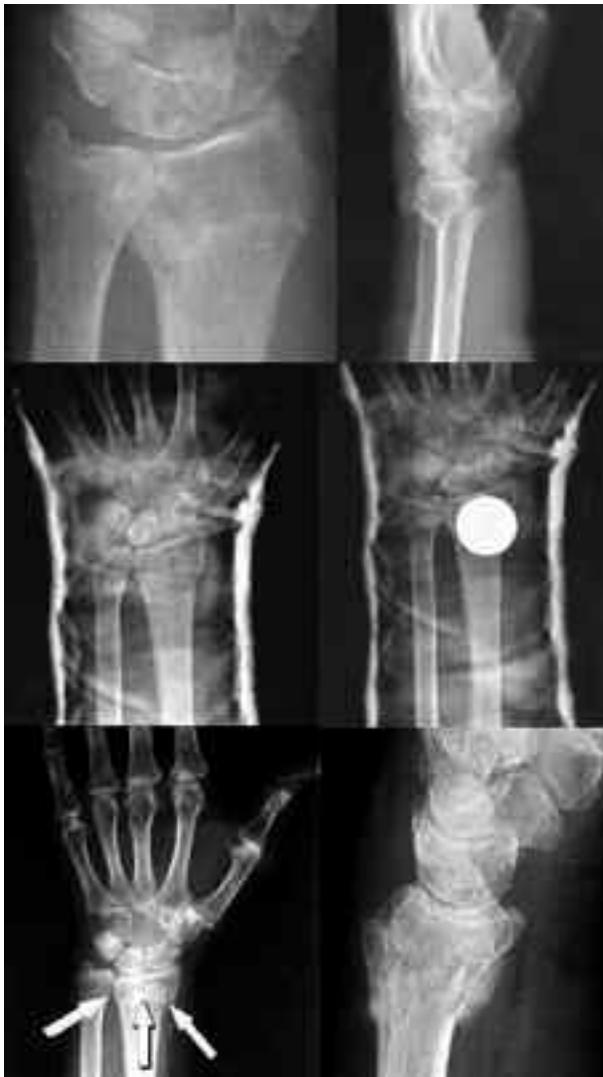

Figure 3. Fracture of the distal epiphysis of the left radius with dorsal dislocation, without metaphyseal fragmentation. X-ray of the fracture after reduction and placement in a plaster cast with and without a magnet and at the removal of the cast with presence of bone callus

Fractures of the wrist with dorsal dislocation and without metaphyseal fragmentation (Fig. 3) were treated with closed reduction after local anesthesia and with immobilization in a synthetic brachioradial-metacarpal plaster cast (combicast) in which a quadrupolar magnet was placed at the same level of the fracture gap. The average immobilization period was of 21.5 days.

Fractures of the wrist with dorsal dislocation and metaphyseal fragmentation were treated with reduc-

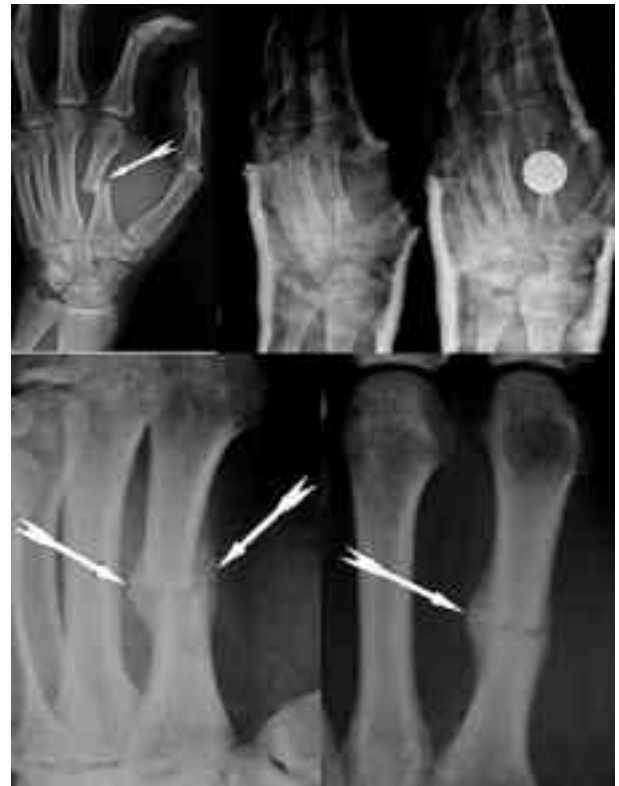

Figure 4. Dislocated fracture of the medial 1/3 second metacarpal of the left hand. X-ray of the fracture after reduction and placement in a plaster cast with and without a magnet and at the removal of the cast with presence of abundant bone callus

tion after local anesthesia and with immobilization in a brachial-metacarpal plaster cast, in which 2 quadrupolar magnets were placed for an average immobilization period of 28 days.

The non-dislocated fracture of the wrist was treated with 10 days of immobilization in a brachioradial-metacarpal plaster cast and 1 magnet, followed by further 13 days in a limited motion brace with the magnet.

Out of the 18 scaphoid fractures, 15 (10 of the body and 5 of the distal pole) were treated with a synthetic brachioradial-metacarpal plaster cast, thumb included, in which a quadrupolar magnet was placed at the same level of the fracture gap.

The average immobilization period in the plaster cast was 23 days.

The 3 remaining fractures (proximal pole) were initially treated with a brachial-metacarpal plaster ca-

st, (average period of 25 days) followed by a brachioradial-metacarpal cast in which a magnet was placed.

The total average immobilization period was of 38 days.

The two non dislocated fractures of the metacarpal bones were treated with a brachioradial-phalanx plaster cast with a quadrupolar magnet for 20 days.

The dislocated fractures of the metacarpal bones (Fig. 4) after reduction with local anesthesia were immobilized in a brachioradial-phalanx plaster cast in which a quadrupolar magnet was placed.

The average immobilization period was of 22 days.

In 3 cases the removal of the plaster cast was followed by setting the hand in a thermoplastic limited motion brace in which the magnet was placed for a period of 15 days.

The four dislocated fractures of the proximal phalanges of the hand were treated, after reduction with local anesthesia, with immobilization in a casted glove with a quadrupolar magnet placed on the edges of the fracture for an average period of 24.6 days.

All the displaced fractures underwent radiological follow-up one week after closed reduction.

After cast removal all the patients were assessed with a clinical and radiological evaluation.

Results

All fractures obtained a good consolidation of the bone without complications.

When the plaster cast was removed the radiological evaluation showed the presence of bone callus associated with the absence of pain in response to digital pressure in the center of the fracture permitting the initiation of the rehabilitative process.

Table 1 summarizes the results obtained reporting the type of fracture, the average time of immobilization in our series, and the average difference in the duration of the immobilization of our cases in comparison with the isolated classical treatment with plaster cast.

Discussion

The use of physical treatments in supporting fracture healing has been widely proven, especially in delays of consolidation and in nonunion.

Among the various physical treatments capable of accelerating the process of bone callus formation, studies regarding the use of pulsed electromagnetic fields and ultrasound waves are common, especially in delayed union and nonunion (12-14).

After studying the above reported cases we wanted to examine the efficiency of natural magnets in the treatment of bone fractures.

More specifically our aim was to "measure" the average times of healing of recent fractures treated with natural magnets in order to compare them with the relative healing times of other treatments discussed in literature.

For such fractures the classic orthopedics texts provide the following methods and treatment periods:

Table 1. Results obtained with the use of natural magnets

Fracture type	Average days of immobilization (plaster cast with natural magnets)	Average difference in the duration (days) of the immobilization
Distal epiphysis of radius with dorsal dislocation without metaphyseal fragmentation	21.5	30-21.5=8.5 (28.3%)
Distal epiphysis of radius with dorsal dislocation and metaphyseal fragmentation	28	37.5-28=9.5 (25.3%)
Distal epiphysis of radius without dislocation	23	30-23=7 (23.3%)
Carpal scaphoid	23.7	45-23.7=21.3 (47.3%)
Metacarpals without dislocation	20	30-20=10 (33.3%)
Metacarpals with dislocation	22	30-22=8 (26,6%)
Phalanges with dislocation	24.6	30-24.6=5.4 (18%)

Wrist fractures: the different nature and severity of the fractures depend on the severity of the fall and the way in which the impact with the ground takes place. When the trauma is mild it is possible that the fracture remains non dislocated; the treatment foresees a simple immobilization in a plaster cast until consolidation is achieved, generally for a period of 30 days. If the trauma is more severe, the distal radial epiphysis can detach in a dorsal and radial direction with a dislocation that can be more or less pronounced; the treatment foresees a non-invasive reduction of the fracture, and immobilization in a plaster cast for a period of 35-40 days; whereas in case of a fracture with multiple fragments with instability of the joints, surgical reduction is necessary.

Fracture of the carpal scaphoid: fractures are classified as stable (tubercle fractures, aligned fractures of the wrist without dislocation) and unstable (oblique, dislocated, comminuted fractures). The stable injuries have a better prognosis and are treated with immobilization in a "long" plaster cast (brachioradial-metacarpal) that includes the first finger for 45 days followed by a radiological evaluation and a clinical control. However, considering the peculiar vascularization of the scaphoid, it is possible to encounter complications such as avascular necrosis, delayed union and non union in which surgical treatment is usually administered.

Metacarpal fractures: in case of a stable fracture the treatment includes immobilization from the wrist to the proximal radial phalanx of the hand for a period of 30 days. In case of an unstable fracture it is necessary to reduce and to immobilize the fracture for a period of 30 days.

Fractures of the phalanx: stable, non-dislocated fractures without deformities, are treated with a metallic splint or immobilized in a cast for approximately 30 days. In case of instable fractures with bone dislocation or rotation of the fragments it is necessary to reduce and to immobilize the fracture for a period of 30 days.

A clinical study regarding ultra-sound waves demonstrated that treatment of recent scaphoid fractures with a plaster cast and low frequency pulsed ultrasounds (US) for 20 minutes a day led to a complete healing of the fracture in 43 days, compared to the 62

days required after treatment with a plaster cast alone, implying a 38% reduction of the immobilization periods (14).

Clinical studies regarding distal radial fractures with bone dislocation such as Pouteau-Colles fractures showed that treatment with a plaster cast and low frequency pulsed US for 20 minutes a day brought to complete healing within 62 days compared to the 98 days required after treatment with plaster cast only.

This implied a reduction of the healing period of 37% (12).

The analysis of our results shows that natural magnets are capable of accelerating the healing of bone fractures in periods that can be compared with those required after treatment with PEMF and US.

A substantial difference lies within the treatment conditions: the use of PEMF or US requires the patient to have the suitable equipment, which consists in a generator of, respectively, magnetic fields and ultrasound waves, that operates on batteries or that can be connected to the electrical current every day for the entire period of treatment. Quadrupolar magnets, on the other hand, are put inside the immobilization device upon its application and remain inside until its removal, acting on the fracture in a constant and continuous manner without actively involving the patient, implying a better quality of life.

Conclusions

From our study it emerges that a fracture, treated with a plaster cast in which a number of quadrupolar magnets capable of sending a constant magnetic flow onto the fracture gap are inserted, shows good bone callus formation in periods that are inferior to "standard" ones of approximately 35%.

This acceleration in the healing of the fracture is important mostly because it reduces the period of immobilization and avoids the excessive weakness and stiffness of the joints involved, that is usually the result of such immobilization.

Moreover, this allows the patient to begin the rehabilitative physiotherapy sooner and to achieve a faster complete functional recovery.

References

1. Bersani F. Premesse fisiche agli effetti biologici dei campi magnetici. Atti del I Congr. Inter. di Magnetoterapia, Rapallo 1979.
2. Barnothy MF. Biological effect of magnetic field, Vol. I and II, Plenum Ed. New York. 1962-1969.
3. Davis CD, Pappion K, Plavienks IM. Bibliography of physiological effects of magnetic field. *Feder Proceed* 1962; 5 (2 suppl): 38.
4. Lenzi M. Sui cosiddetti "effetti radiomimetici" e sulle alterazioni cellulari indotte dai campi magnetici. Exe Med Intern Congress series n. 105; 1965: 1746-52.
5. Alpen EL. Magnetic field exposure guidelines. In: Magnetic field effect of biological systems, Tenford T.S. ED., Plenum Press, New York, 1979.
6. Wolkowsky ZW, Sedak W, Zon J, Jodkowska G. Mechanisme plasmique de la reception du rayonnement electromagnetique a bass frequence par le systemes vivant. Internat Symp on wave therapeutics, p.139-158. Versailles, May 1979. ED. Wolkowsky Z.W., Paris.
7. Chiabrera A, Nicolini C, Schwann HP. Interactions between magnetic fields and cells. Plenum Press, London, 1985.
8. Marconi L, Morgavi G, Ridella S, Rolando C. Ionic phluxes in spherical cells, with non linear membrane, stimulated by an electric field. Bioelectricity, June 1985.
9. Trock DH, Bollt AJ, Markoll R. The effect of PEMF in the treatment of osteoarthritis of the knee and cervical spine. *J Rheumatol* 1994; 21: 1903-11.
10. Saito S, Yamamura I. Electromagnetic fields and biological systems. *Japan J Med E1 and Byol Eng* 1974; 12: 341-9.
11. Chiang H, Shao B. Biological response to microwave radiation: reproduction, development and immunology, electromagnetic interaction with biological systems, New York: Plenum Press, 1989: 141-63.
12. Setter Syed A, Islam MS, Rabbani KS, Talukder MS. Pulsed electromagnetic fields for the treatment of bone fracture. *Bangle Med Res Counc Bull* 1999; 25 (1): 6-10.
13. Mayr E, Rudzki M, Borchardt D, Hausser H, Ruter A. Does low intensity, pulsed ultrasound speed healing of scaphoid fractures? *Handchir Mikrochir Plast Chir* 2000; 32 (2): 115-22.
14. Kristiansen TK, Ryaby JP, McCabe J, Frey JJ, Roe LR. Accelerated healing of distal radial fractures with the use of specific, low-intensity ultrasound. A multicenter, prospective, randomized, double blind, placebo-controlled study. *J Bone Joint Surg Am* 1997; 79 (7): 961-73.

Accepted: 6th november 2007

Correspondence: Cosimo Costantino, MD

Orthopaedics, Traumatology and

Functional Rehabilitation Unit

Department of Surgical Sciences, University of Parma

Parma Hospital, Via Gramsci, 14

43100 Parma. Italy.

Tel: 00390521702144

Fax: 00390521290439

E-mail: cosimo.costantino@unipr.it, www.actabiomedica.it